

A mountain bike is parked on a rocky ledge overlooking a lake and mountains. The bike is black with green accents. The lake is calm, reflecting the surrounding mountains. The sky is clear and blue. The foreground shows dry grass and rocks.

استفاده از دوچرخه به  
عنوان وسیله نقلیه  
یعنی ترافیک کمتر  
پاکی هوا و سلامتی

# Placenta Accrete Spectrum (PAS)

شمسی عباسعلیزاده  
پریناتولوژیست

- ⦿ **Placenta accreta spectrum (PAS)** used to **describe** abnormal trophoblast invasion in to the myometrium, and sometimes to or beyond the serosa.
- ⦿ It is clinically **important** because the placenta does **not** spontaneously **separate** at delivery and attempts at manual removal result in **hemorrhage**.

# Definitions

PAS (formerly called adherent placenta or abnormally invasive placenta) includes three subtypes:

- **Placenta accreta (or creta)** - Anchoring placental villi attach to the myometrium (rather than decidua).
- **Placenta increta** - Anchoring placental villi penetrate into the myometrium.
- **Placenta percreta** - Anchoring placental villi penetrate through the myometrium to the uterine serosa or adjacent organs.

**FIGO classification system describes PAS as follows :**

**Grade 1 -- abnormally adherent placenta: placenta adherenta or creta**

**Grade 2 -- abnormally invasive placenta: increta**

**Grade 3 -- abnormally invasive placenta: percreta**

- ❑ subtype 3a -- limited to the uterine serosa**
- ❑ subtype 3b -- urinary bladder invasion**
- ❑ subtype 3c -- invasion of other pelvic tissue/organs**

**This system also includes clinical and histologic criteria for each grade and subtype.**

**Prevalence in a 2019 :**

**0.01 to 1.1 %**

- **Placenta accreta - 63 %**
- **Placenta increta - 15 %**
- **Placenta percreta - 22 %**



# Pathogenesis Of PAS :

is not known with certainty.

**The most common theory** :defective decidualization area of scarring (thin, poorly formed, partial, absent, or dysfunctional decidua) in an caused by previous uterine surgery allows the anchoring villi of the placenta to attach directly to or invade the myometrium .

## **Other theories(for a proportion of cases):**

microscopic endometrial defects that interfere with normal biological endometrial functions and thereby allow abnormal placental attachment (bicornuate uterus, adenomyosis, or submucous fibroids)

**The factors that regulate the extent of pathologic invasion (eg, accreta versus percreta) are not well defined.**

- ❑ A placenta may have both adherent and invasive villi, and the depth of invasion may evolve with advancing gestation.
- ❑ However, there are confirmed cases of placenta percreta as early as 16 weeks of pregnancy, which suggest that, at least in some cases, the "die is cast" at implantation as to whether an accreta, increta, or percreta will develop and that increasing depth of invasion is not related to increasing duration of gestation.



## **Risk factors :**

- placenta previa after a prior cesarean delivery**(The most important risk factor )  
frequency of PAS increased with an increasing number of cesarean deliveries :
  - **First (primary) cesarean birth, 3 %**
  - **Fifth or greater cesarean birth, 67 %**
  
- cesarean delivery without placenta previa:**
  - **First (primary) cesarean birth, 0.03 %**
  - **Sixth or greater cesarean birth, 4.7 %**
  
- a history of uterine surgery**
  - **myomectomy entering the uterine cavity**
  - **hysteroscopic removal of intrauterine adhesions, cornual resection of ectopic pregnancy**
  - **dilation and curettage**
  - **endometrial ablation**
  - **cesarean scar pregnancy**
  
- maternal age greater than 35 years**
- multiparity**
- history of pelvic irradiation**
- manual removal of the placenta**
- postpartum endometritis**
- infertility and/or infertility procedures**
- multiple gestations**

# Clinical presentation :

- PAS is first **suspected** because of findings on obstetric **ultrasound** examination while the patient is **asymptomatic**.
- It is often diagnosed during prenatal **sonographic screening** of women with a placenta **previa** or a low anterior placenta and prior uterine surgery.
- sometimes the diagnosis is not made until **delivery of the placenta**.

# Clinical Presentation :

- The first clinical manifestation of PAS is usually **profuse, life-threatening hemorrhage** that occurs at the time of attempted **manual placental separation**.
- **part or all of the placenta** remains firmly attached to the uterine cavity, and **no plane** of separation can be developed.
- it also may present as **antenatal bleeding** in **placenta previa**.
- **Hematuria** : Placenta percreta with bladder invasion can cause hematuria during pregnancy (31% ).

**Cystoscopy** is **not** useful for making a preoperative diagnosis(due to microscopic invasion of the bladder)

# Consequences

❖ hemorrhage: is especially severe with more invasive placentation because of greater hyper vascularity of the placental bed.

Potential sequelae of massive hemorrhage include:

- disseminated intravascular coagulopathy
- adult respiratory distress syndrome
- renal failure
- unplanned surgery
- potential complications from transfusion
- death

- ❖ **Peripartum hysterectomy :**
- ❖ **urinary tract damage**
- ❖ **genitourinary fistula**
- ❖ **bowel damage**
- ❖ **thrombotic event**
- ❖ **wound infection**
- ❖ **hemorrhagic shock**
- ❖ **cardiac arrest**
- ❖ **Before delivery, the percreta may compromise the integrity of the previous hysterotomy scar ,predisposing to uterine rupture.**
- ❖ **blood vessels in the pelvis, may be invaded by the placenta.**
- ❖ **Preterm birth**
- ❖ **small for gestational age infants**

**Neonatal outcome is strongly related to gestational age at delivery but does not appear to be significantly affected by depth of placental invasion .**

## **Postpartum placental histology :**

- **Postpartum histologic findings show placental villi anchored directly on the myometrium (accreta ), or invading into the myometrium (increta) or through the myometrium (percreta ), without an intervening decidual plate.**

## Candidates and procedure for screening —

Women with a :

- placenta previa
- or a low anterior placenta and prior uterine surgery

should have thorough transabdominal and transvaginal sonographic evaluation of PAS between approximately 18 - 24w of gestation.

At this gestational age, the prenatal diagnosis of PAS can be made or ruled out with close to 90 %



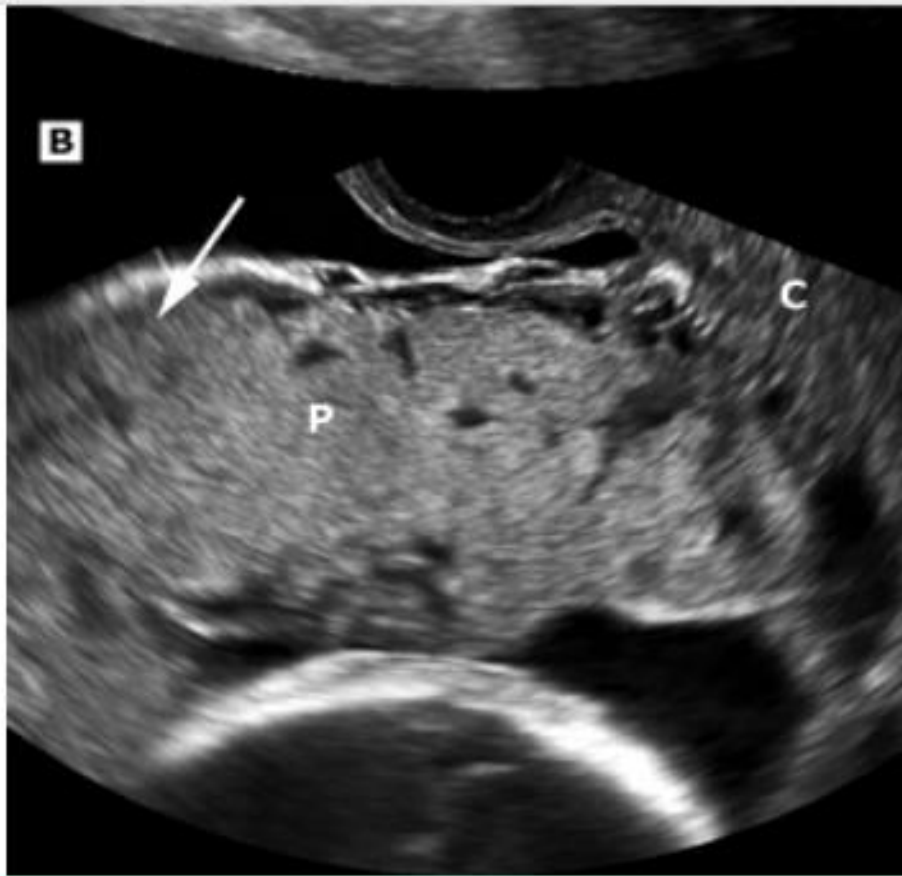
## Ultrasound findings

In the second and third trimesters and in transabdominal and transvaginal sonography:

- ❑ Multiple placental lacunae - Multiple large, irregular intraplacental sonolucent spaces in the center of a lobule or cotyledon adjacent to the involved ("moth-eaten" appearance).
- ❑ Disruption of the bladder line : Loss or disruption of the normally continuous white line representing the bladder wall-uterine serosa interface.
- ❑ Loss of the clear zone : The normal hypoechoic area behind the placenta (termed the "clear space" or "clear zone") may be missing or irregular.
- ❑ Myometrial thinning - The retroplacental myometrium can be thin due to either a prior hysterotomy scar or placental invasion.
- ❑ Abnormal vascularity - Vessels that extend from the placenta through the myometrium either into the bladder or through the serosa.
- ❑ Placental bulge - A portion of the uterus attached to the abnormally adherent placenta can balloon into the bladder due to weakness of the underlying thin myometrium.
- ⦿ Exophytic mass – A focal mass of placenta percreta. that breaks through the uterine serosa, usually extending into the bladder.

all of the findings need not be present .

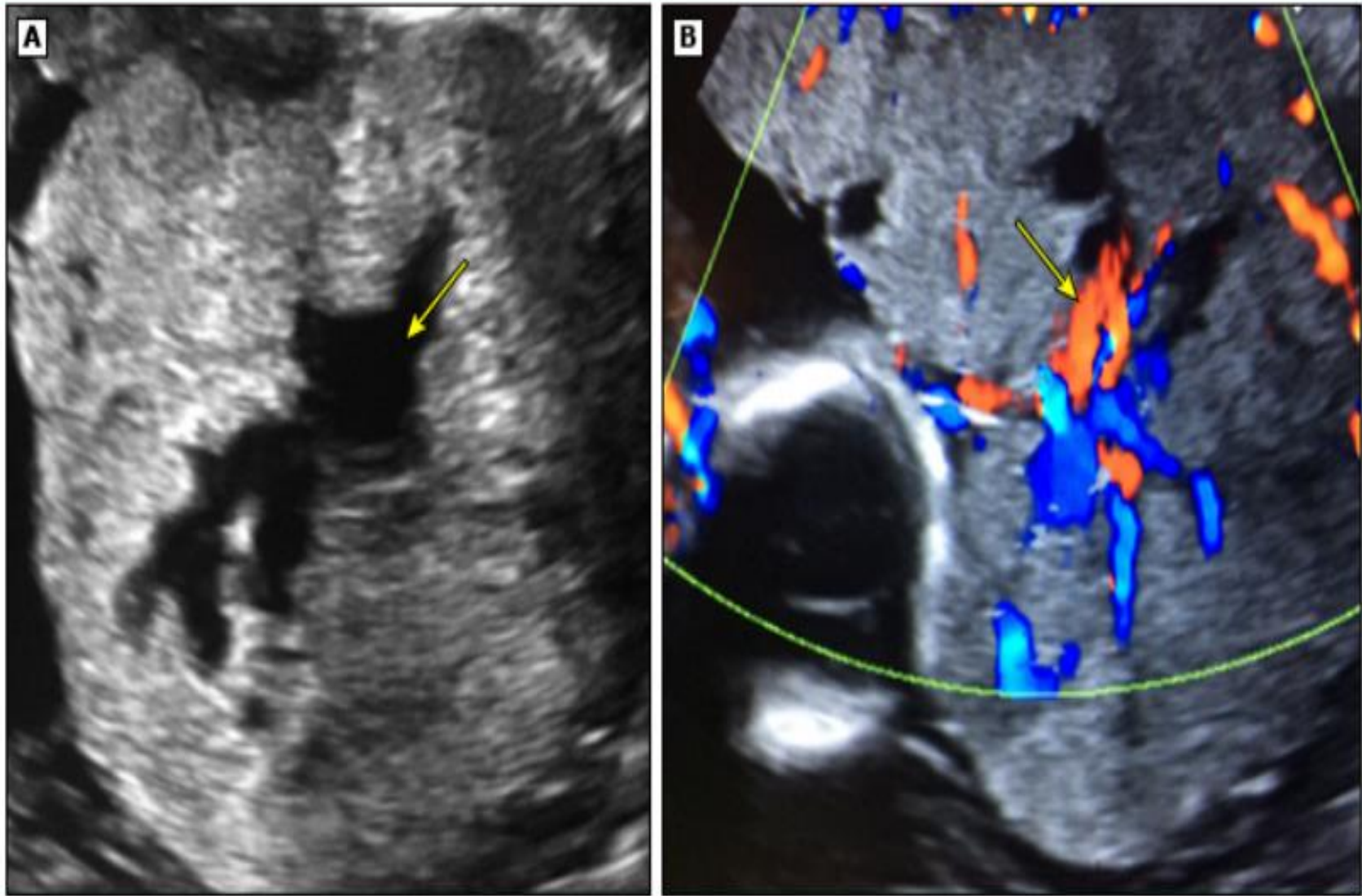
Many of the findings can be **obscured** with **posterior placental location**.



(A) Placenta previa. Sagittal transabdominal scan shows the placenta (P) centered over the cervix (C). There is a normal hypoechoic area between the placenta and the bladder.

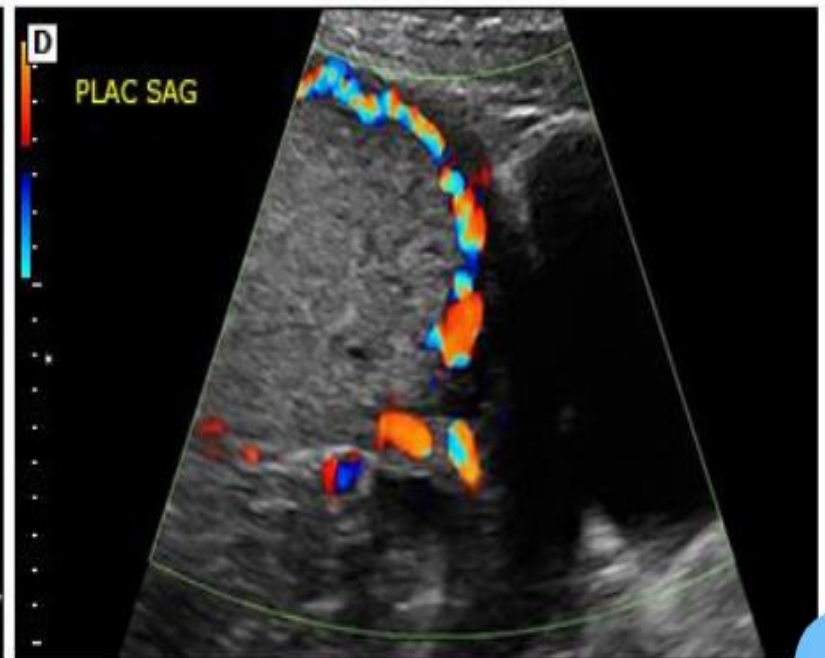
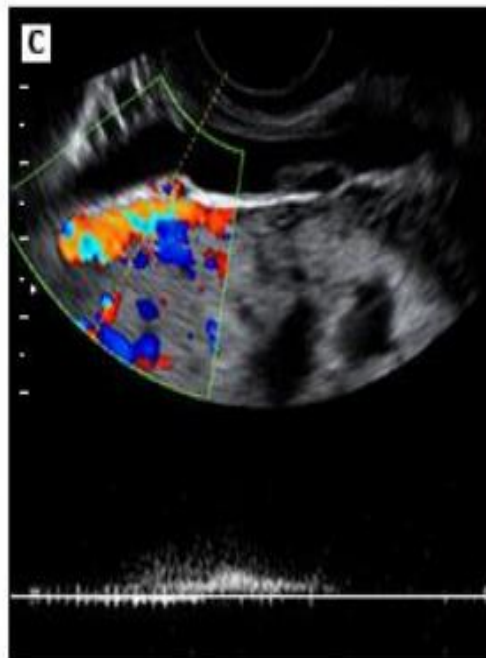
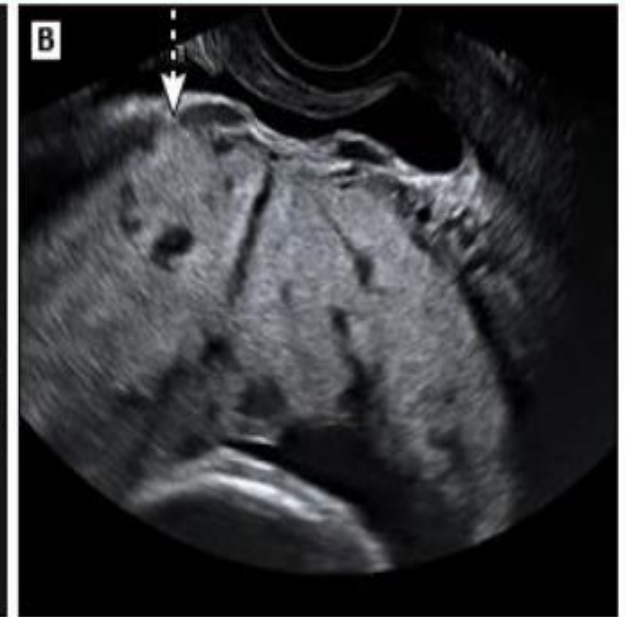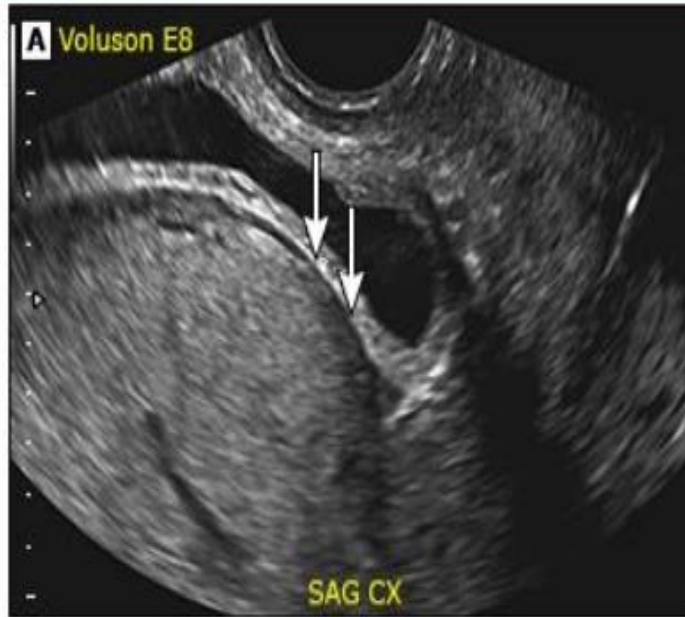
(B) Placenta previa accreta in a different patient from (A). Oblique sagittal transvaginal scan shows the placenta (P) centered over the cervix (C). Note how the placenta invades the myometrium, with loss of the hypoechoic layer of myometrium (arrow), which can be seen in the above panel where the previa is not complicated by accreta.

## Placental lacunae in placenta increta



A transverse transabdominal ultrasound (A) demonstrates tortuous placental lacunae (arrow) confirmed on the color flow Doppler study (B, arrow).

# Ultrasound and Doppler images of placenta accreta





## **Color Doppler**

**Color Doppler is useful for confirming the diagnosis of PAS when used in conjunction with the other ultrasound findings. findings on color Doppler include :**

- **Turbulent lacunar blood flow**
- **Bridging vessels (placental vessels that extend through the myometrium and beyond the serosa into the bladder or other organs.**
- **Hypervascularity of serosa-bladder interface**
- **Prominent subplacental venous complex.**

**Utility of additional imaging techniques** — The role of the following imaging techniques in diagnosis of PAS has not been clearly determined.

❑ **Magnetic resonance imaging (MRI)**

MRI may be more useful than ultrasound in :

- ❖ evaluation of a possible **posterior PAS** because the bladder cannot be used to help clarify the placental-myometrial interface.
- ❖ assessment of the **depth of myometrial and parametrial involvement** and, if the placenta is anterior, bladder involvement.
- ❖ evaluation of the myometrium and **placenta at the most lateral portions of the hysterotomy** as this area is not well visualized by transvaginal ultrasound.

Key factors for high diagnostic performance are ensuring that MRIs are interpreted in conjunction with the ultrasound findings and both are interpreted by physicians with expertise in this area.

If performed, one group considers 24 to 30 w the ideal gestational age for imaging invasive placentation with MRI.

MRI is safe for the fetus, although the use of gadolinium , is avoided in pregnancy due to neurologic, inflammatory, and dermatologic complications to the fetus .

The accuracy of diagnosis with MRI is highly dependent on the expertise and experience of the radiologist interpreting the imaging study.



## **□ Three-dimensional power Doppler ultrasound**

**Diagnostic criteria include:**

- ⊙ Irregular intraplacental vascularization with tortuous confluent vessels crossing placental width.**
- ⊙ Hypervascularity of uterine serosa-bladder wall interface.**

**100 % sensitivity with 92 % specificity**

## First-trimester ultrasound examination

- ◎ PAS should be suspected if first-trimester ultrasound examination reveals:
  - implantation of the gestational sac in the **lower anterior segment** of the uterus, particularly in the niche of the prior cesarean delivery scar
  - placental **lacunae** (intraplacental sonolucent spaces)
  - **disruption** of the interface between the bladder wall-uterine serosa

# **Placenta Accreta Spectrum: Management**

# Prenatal Care

- All patients should be counseled about the diagnosis and potential sequelae (hemorrhage, blood transfusion, cesarean hysterectomy, maternal ICU admission)
- Consultation with a maternal-fetal medicine specialist
- transfer to a center of level III maternal care
- Removal of a cesarean scar pregnancy in the first trimester is likely to reduce maternal risk
- For patients with placenta previa-accreta, prenatal care follows typical guidelines for management of placenta previa
- Nonstress tests and/or biophysical profile scores are not performed routinely but are used in pregnancies that have standard indications for these tests
- Serial sonographic assessment of the placenta is generally not useful after the diagnosis .

## Prenatal Care

- a sonogram at 32 to 34 w can precisely locate the placenta and help to assess the likelihood of bladder involvement.
- Correction of iron deficiency anemia, if present.
- Antenatal betamethasone between 23 - 34 w of gestation for pregnancies at increased risk of delivery within 7 days (eg, antepartum bleeding).
- Anti-D immune globulin if vaginal bleeding occurs and the patient is Rh D-negative.
- Avoidance of pelvic examination and rigorous physical activity.
- Many clinicians recommend avoidance of sexual activity although any benefit is unproven.
- Consideration of hospitalization in the third trimester in the setting of vaginal bleeding, contractions, or residence at a remote distance .
- Asymptomatic women can be followed as outpatients as long as they are appropriately counseled and can get to the hospital rapidly if symptoms develop .

# Preparation For Delivery

- ❑ **Informed consent** - Discussion of potential intraoperative complications and interventions  
(severe hemorrhage, blood transfusion, injury to or partial resection of bladder and bowel, hysterectomy to control bleeding, risk of postoperative vesicovaginal fistula)
- ❑ **Multidisciplinary care team and delivery in a tertiary care**  
(maternal-fetal medicine specialists, anesthesiologists, neonatologists, interventional radiologists, blood bank, nursing personnel, general surgeons who has extensive experience with wide dissection of the parametrium and exploration of the retroperitoneum or gynecologic oncologist, urologists, or urogynecologist, vascular surgeons)

## ❑ Scheduled delivery :

Delivery should be scheduled at a time with optimal availability of necessary personnel and facilities.

However, a substantial percentage of patients develops complications leading to delivery earlier than planned .

In most cases, a **definitive decision** regarding conservative management or cesarean hysterectomy should be made **preoperatively**.

**cesarean hysterectomy** and leaving the placenta undisturbed in situ when the prenatal diagnosis of PAS is reasonably certain based on imaging studies and/or clinical risk factors (placental implantation at the site of prior uterine surgery) is recommend . This approach decreases blood loss and associated complications.

❑ **Intravenous access** ( At least two large bore intravenous catheters )



- ❑ **Thromboembolism prophylaxis** : Pneumatic compression devices (surgery, major hemorrhage, and blood transfusion all increase the risk of postpartum venous thrombosis).
  
- ❑ **availability of blood products**
  
- ❑ **Drugs:**
  - **Tranexamic acid** inhibits fibrin degradation and reduces the risk of death due to postpartum bleeding. However, efficacy specifically in PAS (either as treatment for active bleeding or as a prophylactic agent) is uncertain.
  
  - Use of **recombinant VIIa** for control of obstetric hemorrhage is under investigation

## ❑ Bladder :

- A three-way Foley catheter and ureteral stents should be available .
- Preoperative placement of ureteric stents is useful in all women with PAS, especially those with a percreta, given the likelihood that hysterectomy will be complicated .
- Routine preoperative cystoscopy is not recommended .

❑ Anesthesia : General anesthesia or regional anesthesia(ie, continuous epidural)

❑ Positioning :lithotomy position or with legs flat on the table but separated provides access to the vagina and cervix, to assess bleeding through the vagina.

❑ Postoperative care :

An intensive care unit bed should be available

# Endovascular intervention for hemorrhage control :

Prophylactic endovascular intervention with a balloon catheter in both internal iliac arteries, uterine artery embolization, or a combination of the two may be used to reduce **bleeding during** or after delivery.

The **choice** depends on the operator's **expertise** and the available **equipment**.

The value of endovascular intervention remains **controversial** ,and it is **not** possible to **predict which patients** are most likely to benefit from this procedure .  
(31 % decrease in blood loss and 77 % decrease in blood transfusions )

# Delivery

## Timing :

Women with **active bleeding** should be delivered without a delay to administer antenatal betamethasone .

The risks of **preterm birth** must be **weighed** against the risk of **complications**, such as bleeding , leading to emergency delivery under suboptimal circumstances.

**ACOG**: For stable (no bleeding or preterm labor) patients:

planned delivery between **34+0** and **35+6** w of gestation.

For women at high **risk** of emergency delivery **before 34 w**, planned delivery before 34 weeks may be reasonable, although outcomes are still favorable with emergency delivery in centers of excellence .

# Delivery

Timing :

## Up to date authers:

Most women with no bleeding, contractions, or rupture of membranes remain stable through 36w of gestation . For those who become unstable between 34 and 36 w, outcomes with emergency delivery still appear to be favorable in centers of excellence .

Therefore, we individualize timing of planned delivery within this interval based on clinical symptoms, obstetric history (eg, prior preterm birth), cervical length, and logistical considerations (eg, distance from a center of excellence).

Delivery beyond 36 w is not advised because the favorable effects of expectant management on fetal maturation at this gestational age decrease and are small compared with the increasing and substantial maternal risk if labor leads to hemorrhage.

# Delivery

## Timing :

The Society for Maternal-Fetal Medicine recommends delivery between 34 and 37 w of gestation for stable women with placenta accreta .

international panel suggested delivery at  $\geq 36+0$  w in asymptomatic women (eg, no bleeding, rupture of membranes, or preterm labor) and no history of preterm birth .

They suggested delivery at around 34+0 w in women with a previous preterm birth, multiple episodes of minor bleeding, or a single episode of substantial bleeding.

As discussed above, the authors favor aiming for delivery closer to 34 w of gestation (rather than 36 w) in most cases, although the optimal timing of delivery remains controversial and individualized management is appropriate.

# Procedure

## Cesarean hysterectomy:

- ◉ a vertical midline skin incision , Cherney incision , transverse incision or Pfannenstiel in cases with a low likelihood of intraoperative complications (eg, posterior placenta not extending to the serosa) .
- ◉ The pelvis is inspected for signs of percreta and the location of any collateral blood supply before proceeding with the uterine incision.
- ◉ An intraoperative ultrasound examination for mapping placental edge and determine the best position for the hysterotomy incision, which should avoid transecting the placenta.
- ◉ In cases in which a placenta accreta has been disturbed at delivery and is hemorrhaging, conservative measures are rarely effective and endanger the patient by delaying performance of hysterectomy.



# Procedure

## Cesarean hysterectomy:

- ⊙ After delivery of the infant, the cord is cut, the uterine incision is rapidly closed to decrease blood loss , and hysterectomy is performed.
- ⊙ Prophylactic oxytocin is not administered after the infant is delivered because it may lead to partial placental separation and, increased bleeding .  
if the placenta has been mostly or completely removed or bleeding is heavy, then uterotonic drugs should be given.
- ⊙ We avoid internal iliac (hypogastric) artery ligation because it is time consuming, operator dependent ,ineffective (without hysterectomy) for controlling pelvic hemorrhage in up to 60 % of cases , and precludes use of selective pelvic angiography and embolization if needed subsequently.

- ◉ **Management of placenta percreta with bladder invasion :**
  - Placenta percreta with bladder invasion may require **partial cystectomy**.
  - A urogynecologist, urologist, or gynecologic oncologist should be **consulted** .
  - **Cystoscopy or intentional cystotomy** at surgery is often helpful for assessing the degree of bladder and ureteral involvement .

# Conservative Management Of Placenta Accreta

## ❖ Potential candidates :

- ❑ Patients who **very much want** to preserve **fertility**.  
Such patients should be **counseled** extensively regarding the risks of hemorrhage, infection, possible need for intra- or postoperative lifesaving hysterectomy, and even death, as well as suboptimal outcomes (including recurrence or hemorrhage ) in future pregnancies.
- ❑ When hysterectomy is thought to have an unacceptably **high risk** of hemorrhage or injury to other organs, which may be mitigated by leaving the placenta in situ .
- ❑ When placental resection is thought to be possible because of **focal accreta or a fundal or posterior placenta**.

## ❖ Uterine conservation with the placenta left in situ (expectant management):

- ⦿ the placenta is left in situ after delivery of the newborn.
- ⦿ The umbilical cord is ligated at its placental insertion site.
- ⦿ the hysterotomy is closed in the standard way.
- ⦿ and uterotonic drugs ,compression sutures, intrauterine balloon tamponade, uterine artery embolization, and/or uterine artery ligation are variably used.
- ⦿ **ACOG** indicates that this approach should be attempted **only rarely** or as part of an approved **clinical trial** in fully informed patients .

# Delayed-interval hysterectomy

another option for patients with placenta percreta:  
experience is limited and experts have recommended against it.

it has suggested as an option for only:

- the most severe, potentially life-threatening cases of placenta percreta
- when immediate hysterectomy is too dangerous because of the extent of placental invasion or lack of appropriate resources .

**Adjunctive therapy with methotrexate therapy should not be used:**

There is no convincing evidence that it improves any outcome when the placenta is left in situ,

and there is clear evidence of drug-related harms (pancytopenia, nephrotoxicity) .

## Complications of uterine conservation with the placenta left in situ :

(eg, expectant management, uterine artery embolization, methotrexate therapy, hemostatic sutures, arterial ligation, balloon tamponade) :

- Severe vaginal bleeding: 53 %
- Sepsis: 6 %
- Secondary hysterectomy: 19 %
- Death: 0.3 %
- Subsequent pregnancy: 67 %
- Long-term reproductive outcomes:
  - intrauterine synechiae
  - recurrent placenta accreta( 13 - 29 %).
  - amenorrhea.

❖ Uterine conservation with placental resection maybe successful without excessive risk in two clinical settings:

□ Focal accreta :

- adherent area <50 % of the anterior surface of the uterus and an accessible border of healthy myometrium .
- Desire for future pregnancy
- procedure is likely to be less morbid than the alternative cesarean hysterectomy.

Management involves:

- over sewing the bleeding sites
- or removing a small wedge of uterine tissue containing the focally adherent placenta

□ Fundal or posterior placenta accreta :

- In contrast to anterior placenta accreta, uterine conservation may be possible for a posterior or fundal accreta, since bleeding after removal of placenta accreta in these locations is more readily controlled medically or interventional radiology or conservative surgery.
- The option for hysterectomy is still available if bleeding cannot be adequately controlled
- Recurrence in future pregnancies :22 -29%

# Unexpected Placenta Accreta

## ➤ At cesarean delivery

Upon entering the peritoneal cavity, the surgeon may make the diagnosis of PAS if one or more of the following are seen:

- ◉ Placental tissue invading the lower uterine segment, serosa, or bladder.
- ◉ Increased and tortuous vascularity along the serosa of the lower uterine segment.
- ◉ A bluish/purple and markedly distended lower uterine segment bulging toward the pelvic sidewalls.
- ◉ After delivery of the infant, light traction on the umbilical cord pulls the uterine wall inward, without placental separation.

If the diagnosis is uncertain, then gentle digital exploration for plane of cleavage can be attempted; the absence of a plane is diagnostic.

It is important to distinguish these findings from a placenta normally attached underneath a uterine window (uterine scar dehiscence).



## Management :

If PAS is suspected before the hysterotomy, it is important to **avoid** or minimize **manipulation** sites of PAS .

following approach :

- ⊙ If the patient is **not bleeding heavily, mother and fetus are stable**, and resources for managing these complicated cases are not immediately available, the uterus can be covered with warm packs and **further surgery delayed** until appropriate personnel and other resources are **available**.
- ⊙ If the patient is **not bleeding heavily, mother and fetus are stable**, and assembling these resources is not possible locally, the **abdomen** should be **closed** and the patient **expeditiously transferred** to a facility that can manage these patients, although the risk of massive hemorrhage in transit must be considered.

- If the patient is **not bleeding heavily** and the **fetus is compromised**, the best option is delivery through a **hysterotomy far from the placenta**, followed by closure of the hysterotomy with the **placenta left undisturbed** until appropriate personnel and resources for maternal care are available.

Intraoperative ultrasound can indicate the placental location. If there is no time for ultrasound examination, a hysterotomy in the posterior uterus or fundus will avoid the placenta.

- Women who are **bleeding heavily** or otherwise **unstable** need to be managed as optimally as allowed by the clinical setting and **available resources**.

This includes resuscitation with fluid and blood products, standard surgical procedures for controlling hemorrhage, and **pressure** on bleeding sites(eg, digital, abdominopelvic packs); infrarenal aortic compression can be used in an attempt to control life-threatening hemorrhage. **Direct pressure on a percreta** should be **avoided** or applied cautiously as it may increase the size of the bleeding area.

## Key principles include:

- keeping the patient warm
- rapidly transfusing red cells to restore or maintain adequate circulatory volume and tissue oxygenation
- reversing or preventing coagulopathy by administering fresh frozen plasma and platelets (eg, 1:1:1 or 1:2:4 ratio of packed red blood cells, fresh frozen plasma, and platelets) .

## ➤ At vaginal delivery

- ⊙ Rarely, a focal or complete placenta accreta is first recognized at the time of manual removal of a retained placenta after vaginal delivery.
- ⊙ In these cases, there is **no plane** of cleavage between the myometrium and either the entire placenta or focal areas of the placenta.
- ⊙ Life-threatening **hemorrhage** may occur.
- ⊙ These patients should **receive fluids and transfusion**, as appropriate, while being **prepared for laparotomy** and surgical management (hysterectomy or focal resection), as described above.

# Postoperative Care

An intensive care unit bed should be available for postoperative care, if needed.

These patients may require ventilator support due to pulmonary edema from massive fluid resuscitation or fluid shifts or from acute transfusion-related lung injury .

Some patients need vasopressor support and invasive hemodynamic monitoring.

Postoperative bleeding may occur, and the availability of interventional radiology to provide angiographic embolization of deep pelvic vessels, thus avoiding reoperation, can safely enhance patient care.

Thank you



دوچرخه و سه چرخه وسیله نقلیه پاک

در ترویج دوچرخه سواری میدان را خالی نگذاریم...